

Study on Clinical Profile of Pulmonary Embolism

Siddheshwar M. Rudrakshi¹, Sachin H. Savant², Bennishirur Wasim Ahmed³

Author's Affiliation:

¹Assistant Professor, Department of General Medicine, Ashwini Rural Medical College, Hospital & Research Centre, Kumbhari, Solapur, Maharashtra 413006, India,

²Consultant Physician, Savant Clinic and Jamdar Polyclinic, Akluj, Solapur, Maharashtra, India. ³Statistician cum Assistant Professor, Department of PSM, Dr. VM Govt. Medical College and Shri Chhatrapati Shivaji Maharaj Sarvopchar Rughalay, Solapur, Maharashtra 413003, India.

Corresponding Author:

Sachin Savant, Consultant Physician, Savant Clinic and Jamdar Polyclinic, Akluj, Solapur, Maharashtra, India.

E-mail: drsachinsavant@gmail.com

Received on 02.01.2019,

Accepted on 19.01.2019

Abstract

Background: Pulmonary thromboembolism (PTE) is a major health problem with significant mortality and morbidity. Although rapid advances have taken place in the diagnosis and management of VTE, PE is still an underreported entity from India. We are intended to study various clinical presentations with suspected pulmonary embolism and evaluate the abnormalities in investigations. **Method:** The present study is prospective and observational study, being carried out on suspected cases of pulmonary embolism. All patients admitted during the study period taken as a sample who fulfills inclusion and exclusion criteria. **Result:** Male preponderance (66% cases are male as compared to 34% females) with increased prevalence of pulmonary embolism after the age of forty years. Dyspnea (92%) is the most common presenting symptom followed by chest pain and cough (44% of patients). Hemoptysis was present in 16% of the patients. Most common ECG abnormality in our patients was sinus tachycardia (88%). On CT pulmonary angiography thrombi were found in lobar and segmental branches of pulmonary artery in 90%. **Conclusion:** Early recognition and aggressive and appropriate therapy improves outcome in this potentially fatal condition. Prevention of VTE in high-risk cases by lifestyle modification and early ambulation in hospitalized cases especially in Indian setting should be universally practiced. More emphasis need to be given on the high index of suspicion, early and appropriate diagnostic tests, prompt therapy, and preventive measures to improve the outcome in VTE patients.

Keywords: Pulmonary Embolism; Venous Thromboembolism; ECG; CT Pulmonary angiography.

Introduction

Pulmonary thromboembolism (PTE) is a major health problem with significant mortality and morbidity. Venous Thromboembolism (VTE), which consists of Deep Vein Thrombosis (DVT) and Pulmonary Embolism (PE), is a potentially fatal disease. Long term sequelae particularly post phlebotic syndrome (PPS) are frequent and often disabling [1].

Acute pulmonary embolism (PE) is a major cause of death associated with surgery, injury, and medical illnesses. Pulmonary thromboembolism is responsible for up to 15% of all in-hospital deaths. Overall, the annual incidence of pulmonary embolism ranges between 23 and

69 cases per 100,000 population [3] with an average case fatality rate within 2 weeks of diagnosis of approximately 11% [4] roughly accounting for at least 100,000 deaths each year.

Among cardiovascular diseases, VTE along with stroke and myocardial infarction rank as three big cardiovascular killers [5,6].

Although rapid advances have taken place in the diagnosis and management of VTE, PE is still an underreported entity from India. Most of the reports are limited to autopsy reports and short case series [7-12]. However, with the advent of spiral computed tomography (CT), there is now an increased recognition of this entity in India.

The nonspecificity of clinical manifestations and limited availability of complementary methods are

the main obstacles to diagnosis. Complementary tests are essential for diagnosis of patients with clinical suspicion and to evaluate prognosis of those with an already diagnosed PE.

Pulmonary embolism has earned the reputation of a silent killer because less than half of patients who die of pulmonary embolism are diagnosed with the problem prior to death [13].

Diagnosis of PE is based on clinical suspicion, demonstration of thrombus in leg veins and in pulmonary vasculature. The clinical symptoms, physical examination, routine tests like ECG, X Ray chest are often nonspecific thus requiring a high index of suspicion in high risk populations. Various clinical scoring systems [14] and diagnostic workup protocols have been proposed to improve the sensitivity and specificity of diagnosing PE. Spiral computed tomographic pulmonary angiography (sCTPA) is the most reliable modality to confirm diagnosis of PE [15]. It is quick, specific, provides additional information regarding RV dilatation and function. Ventilation/ perfusion (V/Q) scan may be helpful but is often non diagnostic; normal scan however rules out PE. MRI may be used but does not detect thrombi in smaller pulmonary arteries. Pulmonary angiography may be used especially when a catheter based therapy is planned. Demonstration of thrombus in leg veins by Ultrasound, contrast CT, MRI or conventional venography may increase the diagnostic accuracy [16]. D-Dimer assay may help in patients with low and intermediate probability of pulmonary embolism; patients with normal values do not require further tests or treatment [17].

Diagnosing pulmonary embolism requires high index of suspicion and recognizing this entity early in the course of disease is important because if treated early mortality can be reduced from 30% to 8%.

In the present study we intend to study various clinical presentation with suspected pulmonary embolism and evaluate the abnormalities in investigations like Electrocardiogram (ECG), Chest x-ray, Arterial Blood Gas (ABG), Venous Doppler of lower limbs, 2D Echocardiography and CT Pulmonary angiography.

Material and Methods

The present study is prospective and observational study, being carried out on suspected cases of pulmonary embolism which are then confirmed by CT pulmonary angiography. Our study is done on patients admitted in Intensive care unit over a period of two years.

All patients admitted during the study period taken as a sample who fulfills inclusion and exclusion criteria.

Inclusion criteria

- All cases of pulmonary embolism suspected on the basis of clinical presentation by using Wells score, ECG and 2D ECHO findings then these cases evaluated by CT Pulmonary angiography and only confirmed cases are included in the study.
- Males and females above 18 year of age.
- CT pulmonary angiography showing evidence of pulmonary embolism

Exclusion criteria

- Patients below 18 years of age.
- Patients of Heart failure and COPD with Cor-pulmonale.
- Lack of evidence of pulmonary embolism on CT pulmonary angiography.

Data collection method

The study was approved by the ethical committee. Informed consent in English and patients own language was taken before enrollment. Detailed history and clinical examination of each case was done. Clinical history was obtained from the attendee when patient is unable to give history. Patients of pulmonary embolism are clinically suspected by using Wells score [18];

1. clinically suspected DVT – 3.0 points
2. alternative diagnosis is less likely than PE – 3.0 points
3. tachycardia (heart rate > 100) – 1.5 points
4. immobilization (\geq 3d)/surgery in previous four weeks – 1.5 points
5. history of DVT or PE – 1.5 points
6. hemoptysis – 1.0 points
7. malignancy (with treatment within 6 months) or palliative – 1.0 points

Traditional interpretation

Score > 6.0 – High (probability 59% based on pooled data)

Score 2.0 to 6.0 – Moderate (probability 29% based on pooled data)

Score < 2.0 – Low (probability 15% based on pooled data)

Alternative interpretation

Score > 4 – PE likely. Consider diagnostic imaging.

Score 4 or less – PE unlikely. Consider D-dimer to rule out PE.

Risk factors for pulmonary embolism

Deep vein thrombosis: The most common sources of embolism are proximal leg deep venous thrombosis (DVTs) or pelvic vein thromboses. Any risk factor for DVT also increases the risk that the venous clot will dislodge and migrate to the lung circulation, which may happen in as many as 15% of all DVTs.

The development of thrombosis is classically due to a group of causes named Virchow's triad (alterations in blood flow, factors in the vessel wall and factors affecting the properties of the blood). Often, more than one risk factor is present.

1. *Alterations in blood flow:* immobilization (after surgery, injury), pregnancy (also procoagulant), obesity (also procoagulant), cancer (also procoagulant).
2. *Factors in the vessel wall:* surgery, catheterizations causing direct injury ("endothelial injury")
3. *Factors affecting the properties of the blood (procoagulant state):*
 1. Estrogen-containing hormonal contraception.
 2. Genetic thrombophilia (factor V Leiden, prothrombin mutation G20210A, protein C deficiency, protein S deficiency, antithrombin deficiency, hyperhomocysteinemia and plasminogen (fibrinolysis disorders).
 3. Acquired thrombophilia (antiphospholipid syndrome, nephrotic syndrome, paroxysmal nocturnal hemoglobinuria).
 4. Cancer (due to secretion of pro-coagulants)
- Investigation studied
 1. CBC: Leukocytosis
 2. D- dimer ELISA
 3. Cardiac biomarkers like cardiac troponin increased because of RV microinfarction
 4. ECG:
 - 1) Sinus tachycardia was defined as an increase in sinus rhythm to > 100 beats/min.

2) The SI Q3 T3 pattern was defined according to the criteria of McGinn and White [83].

{S wave in lead I and Q wave in lead III, with an amplitude of more than 0.15 mV (1.5 mm) associated with inversion of the T wave in lead III}.

3) Anterior subepicardial ischemic aspect (negative T waves) was defined by the presence of pointed and symmetrical inverted T waves from V1 to V4 or beyond sometimes with QT prolongation.

4) Right bundle branch block

5) Right axis deviation etc.

6) Low QRS voltage was determined when the amplitude of the largest QRS deviation in the peripheral leads was <5 mm.

7) A "pulmonary" P wave was determined when its amplitude reached 0.25 mV (2.5 mm) in lead II.

5. *Chest X ray:* chest x ray is normal or nearly normal in PE.

6. *2D Echocardiography:* Dilatation of right atrium and right ventricular, increased pulmonary arterial pressure, Dyskinesia of right ventricular.

7. *Venous Doppler of lower limbs*

8. *Arterial blood gases:* Lacks the diagnostic utility, even though both Po₂ and Pco₂ often decrease.

9. *CT pulmonary Angiography:* Cardinal CT sign of PE is intraluminal filling defect which is central diagnostic criteria for pulmonary embolus.

Statistical analysis: Descriptive statistics such mean, SD and percentage was used to present the data. Microsoft excel was used to generate tables and graphs.

Results

Most of the patients belong to the age group 41-50 yrs (26%). Male patients (66%) were more compared female patients (34%) (Fig. 1).

In present study most common risk factor was age > 40 yrs (66%) followed by previous history suggestive of DVT (44%) (Table 1).

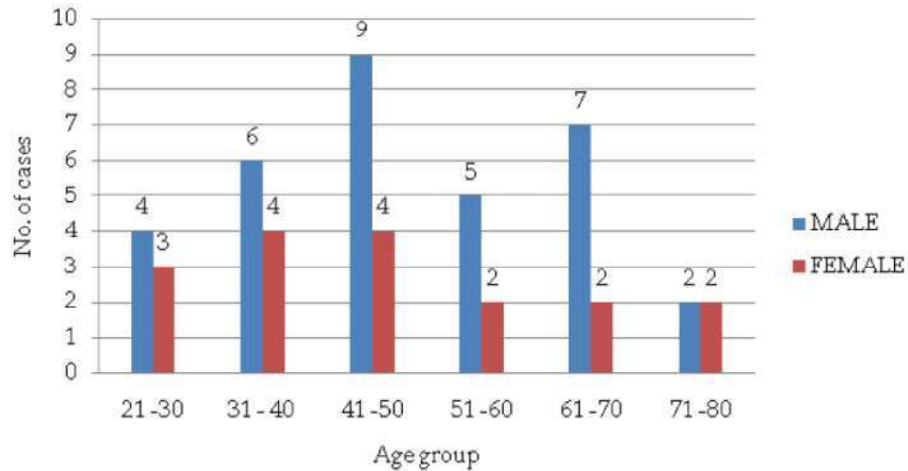


Fig. 1: Age and sex wise distribution of patients with pulmonary embolism

Table 1: Risk factors and co morbidities

Risk factor/ Co morbidity	No. of Patients	Percentage
Age > 40 yrs	33	66%
Bed rest > 72 hrs	02	04%
Previous history s/o DVT	22	44%
COPD	04	08%
CCF	03	06%
Smoking /tobacco	21	42%
Obesity (BMI >30)	03	06%
Hypertension	10	20%
Diabetes mellitus	07	14%
Surgery	02	04%
Hyperlipidemia	09	18%
Pregnancy/ postpartum	01	02%
OC pills	01	02%
Hip/ lower limb fracture	01	02%
Idiopathic	05	10%

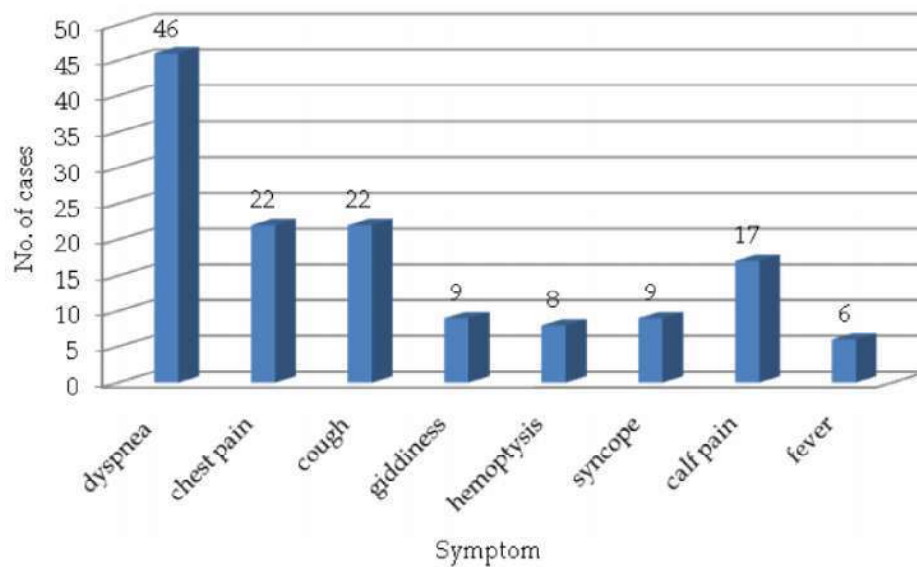


Fig. 2: Symptomatology

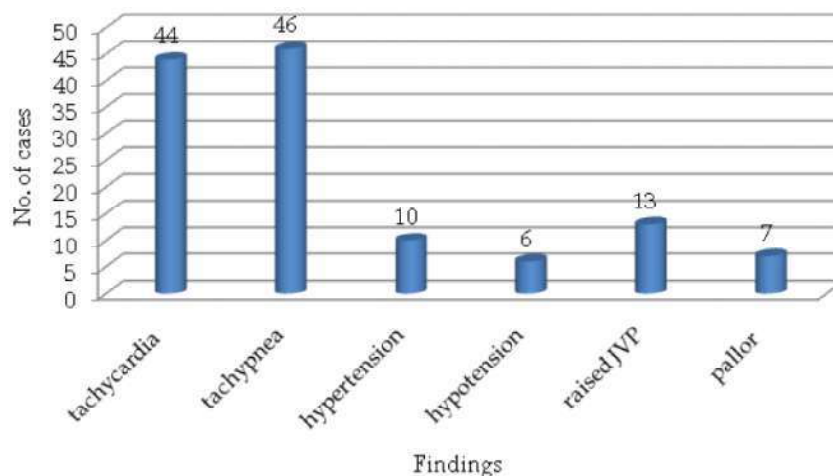


Fig. 3: General examination

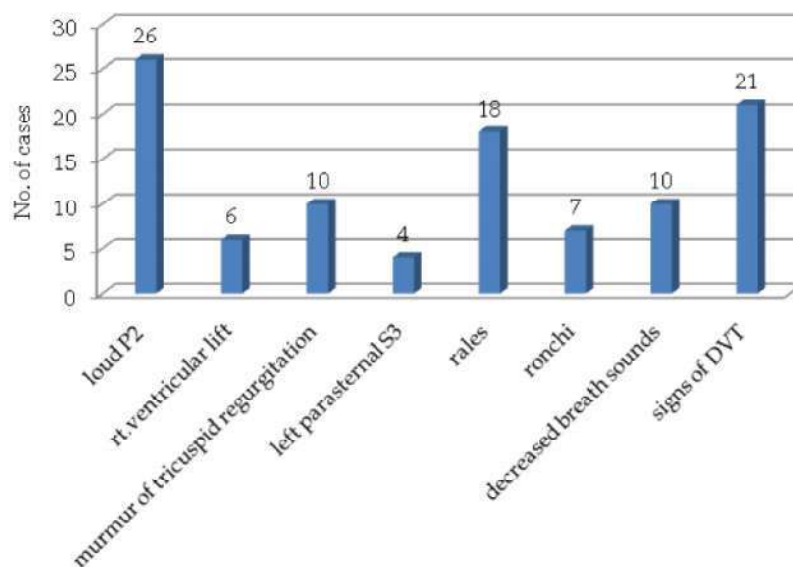


Fig. 4: Systemic examination

In present study, dyspnea (92%) was the most common symptom followed by cough (44%) and chest pain (44%) (Fig. 2).

In present study tachypnea (92%) was the most common finding on general examination followed by tachycardia (88%) (Fig. 3).

Loud P2 (52%) was the most common finding on systemic examination followed by signs of DVT (42%) and Rales (36%) (Fig. 4).

Table 2: Blood investigations

Investigation	No. of Patients	Percentage
Hb < 10 gm%	07	14%
Deranged KFTs	03	06%
Deranged LFTs	02	04%
Hyperlipidemia	09	18%
ABG showing e/o hypoxemia	45	90%
Hyperglycemia	08	16%

Hypoxemia (90%) on arterial blood gas analysis was the most common abnormality on blood investigation in present study followed by hyperlipidemia (18%) (Table 2).

Table 3: Chest X ray findings

Finding	No. of Patients	Percentage
Normal CXR	24	48%
Cardiomegaly	13	26%
Pleural effusion	07	14%
Hilar congestion	04	08%
Prominent central pulmonary artery	06	12%
Hamptons hump	02	04%
Oligemic lung field	01	02%
Infiltrates	07	14%

In present study 48% patients had a normal chest X ray, cardiomegaly (26%) on chest X ray was the second most common finding (Table 3).

Table 4: 2 D Echocardiography and color Doppler findings

Finding	No. of Patients	Percentage
RA and RV dilatation	42	84%
Tricuspid regurgitation	45	90%
Mild pulmonary hypertension (SPAP 20-40 mm of Hg)	03	06%
Moderate pulmonary hypertension (SPAP 40-60mm of Hg)	17	34%
Severe pulmonary hypertension (SPAP >60mm of Hg)	25	50%
Normal 2 D Echo	05	10%

In present study tricuspid regurgitation (90%) was most common finding on 2D Echocardiography (Table 4).

Table 5: Location of thrombus on CT pulmonary angiography

Location	No. of Patients	Percentage
Main pulmonary artery	06	12%
Right branch of main pulmonary artery	12	24%
Left branch of main pulmonary artery	03	06%
Both branches of main pulmonary artery	23	46%
Lobar and segmental branches	45	90%

In present study lobar and segmental location (90%) of thrombus was most common finding on CT Pulmonary angiography (Table 5).

Table 6: Electrocardiographic changes

Finding	No. of Patients	Percentage
Sinus tachycardia	44	88%
S1Q3T3 pattern	14	28%
Right axis deviation	10	20%
Right bundle branch block	05	10%
P pulmonale	06	12%
R in aVR	07	14%
T wave inversion in II, III, aVF	16	32%
T wave inversion in V1 - V3	36	72%
Low voltage ECG	04	08%
Normal ECG	04	08%

In present study sinus tachycardia (88%) was the most common ECG abnormality followed by T wave inversion in V1 - V3 (72%) (Table 6).

Discussion

Age and Sexwise Distribution

Pulmonary embolism was observed in all age groups with a tendency to increase occurrence after the age of 40 years. The mean age observed in our study was 48 years which is lower than those observed in the ICOPER [19] (62.3 years), MAPPET [20] (63.5 years) and JASPER [21] (60 years) studies.

Most studies show a tendency towards even distribution by gender. In our study we observed a higher prevalence of the male gender (66%), which was also almost consistent with the MAPPET study (59%) [20].

Risk Factors and Comorbidities

Analysis of risk factors identified age over 40 years (66%) and previous history suggestive of DVT (44%) as the most prevalent, corroborating epidemiological data in literature [22].

The emergence of endothelial degenerative changes associated with presence of diseases that predispose to thrombus formation, are more frequently seen in patients over 40 years of age this explains the high prevalence of this risk factor. With the increasing life expectancy of the population, age should become an increasingly prevalent risk factor.

The endothelial changes caused by a first episode of deep vein thrombosis (DVT) predispose to disease recurrence. Previous occurrence of DVT had been reported in 44% of our cases, which is higher than 25% in ICOPER [19] and 29% in MAPPET [20]. These observations indicate possible benefit of continued use of elastic stockings for such patients.

A hip or lower limb fracture was documented in 2% of the sample, which is lower than other studies JASPER [21] (9%) and MAPPET [20] (11%). Similar differences are also observed in the history of abdominal or pelvic surgery, with prevalence of 4% in our sample and 36% in JASPER [21] and 27% in MAPPET [20]. This difference can be explained by the characteristics of hospitals involved in each of the studies.

Tobacco use (smoking/chewing) was reported by 42% of patients and quitting should be encouraged as it is one of the few risk factors considered modifiable.

As co-morbidity, hypertension in 20% and diabetes mellitus in 14% in our study and hyperlipidemia was observed in 18% of the patients. All of these factors may play a contributory role by increasing the endothelial dysfunction.

Symptomatology

In the present study, dyspnea was present in 92%, a bit higher to the result of Stein et al. [23] that demonstrated presence of dyspnea in 78% and Hoellerich et al. [24] in 74%.

Pleuritic chest pain is more correlated with the PE, but angina pain may occur in patients with ischemia of the right ventricle (RV). In this study a prevalence of 44% of chest pain was found, similar to the findings of ICOPER [19] (49%) and JASPER [21] (46%).

Chest pain was reported in 85% of patients in the Bell et al. [25] study and 66% in the PIOPED study [26].

Cough was present in approximately 44% of our patients, with a comparable prevalence in the two studies of Stein et al. that documented it in 37% and 55% of patients [23,27].

Hemoptysis was observed in 16% of cases in our study, while in 13% of patients in study by Stein et al. [23].

Fever was observed in 12% of patients, similar to the 14% reported in all the subjects studied by PIOPED [26], demonstrating the importance of differential diagnosis of PE in inflammatory lung diseases [28].

Syncope was observed in 18% of our patients which are similar to that found in 14% in ICOPER [19] and 20% in JASPER [21].

General Examination

In the present study on general examination, it was found that, tachycardia (pulse rate >100 /min) in 88% of our patients and tachypnea (respiratory rate >20) in 92% of our patients. This is a little higher with the MAPPET [20] study which found the prevalence of tachycardia in 71% patients and 70% by Stein et al. [23].

Hypertension was found in 20% of patients in our study. This was because of preexisting hypertension and more prevalence of elderly subjects.

Clinical signs of hemodynamic instability were present in 12% of our patients. In ICOPER [19], only 5% had hypotension, while MAPPET [20] and JASPER [21] showed higher prevalence (34% and 36% respectively) than our observations. Not with standing these differences there is agreement that this is a greater severity subgroup giving rise to grater morbidity and mortality.

Raised JVP was found in 26% patients higher than study by Stein et al. (13%) [23]. This might be

due to more number of cases with right ventricular dysfunction as compared with other study.

Systemic Examination

The examination of cardiovascular system revealed accentuation of pulmonic component of second heart sound which was the most prevalent finding on auscultation with a prevalence of 52% in the present study. A study by Stein et al. reported this finding in 15% cases this difference might be due to more number of minor PE cases [23].

A right ventricular S3 was found in 8% of our patients. A right ventricular lift (left parasternal heave) was present in 8%, this finding was near to comparable with study by Stein et al. [23].

Most common finding on examination of respiratory was presence of rales which was found in 36% of our patients. This finding was also the commonest respiratory finding in study by Stein et al. (21%) [23].

We found signs of deep venous thrombosis (Edema, erythema, tenderness, or palpable cord Homans sign, Moses sign) in 42% of our patients. It is similar to prevalence of 47% found in study by Stein et al. [23].

Blood Investigations

In our study, evidence of low PaO₂ (hypoxemia PaO₂ < 80 mm of Hg while breathing room air) on arterial blood gas analysis in 90% is higher than study by Stein et al. [23] based on PIOPED II data. This low arterial PaO₂ is attributed to the ventilation perfusion mismatch created due to the effect of thrombus in pulmonary circulation.

We found hyperlipidemia in 18% of our patients which represents modifiable risk factors for PE as well as other cardiovascular conditions. Whereas hyperglycemia was present in 16% patients as the second most common metabolic abnormality after hyperlipidemia.

Chest Radiography

The majority of patients with pulmonary embolism have abnormal chest radiographs [29]. However, these abnormalities are usually subtle, nonspecific, and therefore non diagnostic.

The major role of chest radiography in suspected pulmonary embolism was to exclude competing diagnoses and to evaluate the pulmonary parenchyma.

In present study, chest radiographic changes in 52% of patients, whereas 78% of patients in ICOPER [19].

The ICOPER showed that pleural effusion was present in 23%, and areas of pulmonary infiltrates in 17% [19]. Our findings identified pleural effusion in 14%, and pulmonary infiltrates in 14% of patients.

2 - D Echocardiography and Color Doppler:

Tricuspid regurgitation was the most common finding observed in 90% patients in our study.

The percentage of patients with RV dysfunction on echocardiography was 84%, which is higher than study by Ribeiro et al. [30] (70%). Severe pulmonary hypertension was found in 50% of patients.

2 D Echocardiography was normal in 10% of our patients corroborating the fact that normal 2 D Echo does not exclude the diagnosis of pulmonary embolism.

Location of Thrombus on Ct Pulmonary Angiography

In our study the location of thrombus on CT Pulmonary angiography was in 90% cases thrombus was found in lobar and segmental branches.

In 46% of patients thrombus was located in both main branches of pulmonary artery and in 12% patients thrombus was located in the main pulmonary artery

24% of our patients had thrombus located in right pulmonary artery and 6% had the thrombus located in left pulmonary artery.

Electrocardiographic Changes

In the present study, the ECG changes were present in 92% of cases. This marked prevalence of ECG changes should be attributed to the fact that the patients were habitually receives cases of submassive and massive PE.

Our study shows sinus tachycardia as the most prevalent (88%) ECG abnormality which is comparable with study by Lenegre et al. (90%) [31].

T wave inversion in V1 to V4 (anterior subepicardial ischemic pattern) was the next most common abnormality observed in 72% of our patients. This is in agreement with a study by Ferrari et al. (68%) [32] and Lenegre et al. (89%) [31].

In a series of 12 patients with massive PE and an ECG appearance of subepicardial ischemia in the anterior region, a very early myocardial scintigraphy with MIBI concomitant with the

existence of these ECG signs did not demonstrate any perfusion defect evocative of ischemia [33].

Negative T waves in precordial leads are accompanied in almost 50% of cases by negative T waves in inferior leads. However, the latter are more transient.

The S1Q3T3 pattern was observed in 28% of our patients the prevalence of this classic sign of PE appears to be less. A similar prevalence of 28% was reported by Cutforth et al. [34] but the studies by Ferrari et al. [32] and Lenegre et al. [31] report prevalence of this abnormality to be 50% and 52% respectively.

Right Bundle Branch Block was seen in 10% of our patients which is in agreement with a study by Stein et al. (15%) [35].

Right axis deviation was seen in 8% in our study and the prevalence of low voltage ECG in our study was also 8%. This is similar to study by Stein et al. [105] who showed the prevalence of 6% for this abnormality.

Whereas a normal ECG was observed in 8% of our patients a similar prevalence has been observed in a study by Ferrari et al. [32] and Lenegre et al. [31] who reported it to be 9% and 13% respectively. This stresses the fact that a normal electrocardiogram does not rule out pulmonary embolism.

Conclusion

VTE is a common cause of mortality and morbidity in patients hospitalized for surgical or medical illnesses. It is often misdiagnosed and not treated in time. Signs and symptoms are nonspecific and high degree of clinical suspicion with right application of diagnostic tools both imaging and non-imaging are vital for definitive diagnosis. With increasing availability of radiographic techniques the likelihood of diagnosing this condition has improved. Prevention of VTE in high-risk cases by lifestyle modification and early ambulation in hospitalized cases especially in Indian setting should be universally practiced. More emphasis need to be given on the high index of suspicion, early and appropriate diagnostic tests, prompt therapy, and preventive measures to improve the outcome in VTE patients.

References

1. Prandoni P, Lensing AW, CogoA, et al. The long term Clinical Course of Acute Deep Vein Thrombosis. *Ann Intern Med.* 1996;125:1-7.

2. Agarwala S, Bhagwat A, Sharma A, et al. Local and general factors are the likely cause of venous thrombosis in lower limb arthroplasty. *ThrombHaemost.* 2004;92:1167-9.
3. Silverstein MD, Heit JA, Mohar DN, Petterson TM, O' Fallon WM. Trends in the incidence of deep vein thrombosis and pulmonary embolism: a 25 year population based study. *Arch Intern Med* 1998;158:585-93.
4. Goldhaber SZ, Visani L, De Rosa M. Acute pulmonary embolism: clinical outcomes in the International Cooperative Pulmonary Embolism Registry (ICOPER). *Lancet.* 1999;353:1386-89.
5. Anderson FA Jr, Wheeler B, Goldberg RJ, et al. A population-based perspective of the hospital incidence and case fatality rates of deep vein thrombosis and pulmonary embolism: the Worcester DVT study. *Arch Intern Med.* 1991;151:933-38.
6. Giuntini C, Ricco GD, Marini C, et al. Pulmonary embolism: epidemiology. *Chest* 1995; 107(suppl):35-9S.
7. Reddy CR, Jagabandhu N. Thromboembolic complications seen at autopsy in South India. *Arch Pathol.* 1967;83:399-402.
8. Poulouse KP, Sahajanandan VK. The incidence and diagnosis of pulmonary embolism. *J Assoc Physicians India.* 1973;21:45-49.
9. Shead GV, Narayanan R. Incidence of postoperative venous thromboembolism in South India. *Br J Surg* 1980;67:813-4.
10. Datta BN, Ramesh K, Bhusnurmath B. Autopsy incidence of pulmonary vascular episodes: a study of 218 cases. *Angiology.* 1986;37:744-50.
11. Saxena R, Mohanty S, Srivastava A, Choudhry VP, Kotwal J. Pathogenetic factors underlying juvenile deep vein thrombosis (DVT) in India. *Eur J Haematol.* 1999;63:26-8.
12. Gowrinath K, Reddy GK. CT appearances in patient with pulmonary thromboembolism and infarction. *Indian J Chest Dis Allied Sci.* 2003;45:116-20.
13. Bagaria V, Modi N, Panghate A, et al. Incidence and risk factors for development of venous thromboembolism in Indian patients undergoing major orthopaedic surgery: results of a prospective study. *Postgrad Med J.* 2006;82:136-9.
14. Wells PS, Anderson DR, Roger M, et al. Excluding pulmonary embolism at the bedside without diagnostic imaging : management of patients with suspected pulmonary emboli presenting to the emergency department by using a simple clinical model and D-dimer. *Ann Intern Med* 2001;135:98-107.
15. Stein PD, Fowler SE, Goodman LR, et al. Multidetector computed tomography for acute pulmonary embolism. *N Engl J Med.* 2006;354:2317-27.
16. Perrier A, Howath N, Didier D, et al. Performance of helical computed tomography in unselected outpatients with suspected pulmonary embolism. *Ann Intern Med.* 200;135:88-97.
17. Torbicki A, Perrier A, Konstantinides SV, et al. Guidelines on the diagnosis and management of Acute Pulmonary Embolism of European Society of Cardiology. *Eur Heart J.* 2008;29:2276-15.
18. Neff MJ et al. ACEP releases clinical policy on evaluation and management of pulmonary embolism. *American Family Physician.* 2003;68(4): 759-60.
19. Goldhaber SZ, Visani L, De Rosa M. Acute pulmonary embolism: clinical outcomes in the International Cooperative Pulmonary Embolism Registry (ICOPER). *Lancet.* 1999;353(9162):1386-9.
20. Kasper W, Konstantinides S, Geibel A, Olschewski M, Heinrich F, Grosser KD, et al. Management strategies and Determinants of outcome in acute major pulmonary embolism: results of a multicenter registry. *J Am Coll Cardiol.* 1997;30(5):1165-71.
21. Nakamura M, Fujioka H, Yamada N, Sakuma M, Okada O, Naganishi N, et al. Clinical characteristics of acute pulmonary thromboembolism in Japan: results of a multicenter registry in the Japanese Society of Pulmonary Embolism Research. *Clin Cardiol.* 2001;24(2):132-8.
22. Anderson FA Jr, Wheller HB, Goldberg RJ, Hosmer DW, Patwardhan NA, Jovanovic B, et al. A population-based perspective of the hospital incidence and case-fatality rates of deep vein thrombosis and pulmonary embolism. The Worcester DVT Study. *Arch Intern Med.* 1991;151(5): 933-8.
23. Stein PD, Willis PW 3rd, De Mets DL. History and physical examination in acute pulmonary embolism in patients without preexisting cardiac or pulmonary disease. *Am J Cardiol.* 1981;47(2):218-23.
24. Hoellerich VL, Wigton RS. Diagnosing pulmonary embolism using clinical findings. *Arch Intern Med.* 1986;146(9):1699-704.
25. Bell WR, Simon TL, DeMets DL. The clinical features of submassive and massive pulmonary emboli. *Am J Med.* 1977;62(3):355-60.
26. Value of the ventilation/perfusion scan in acute pulmonary embolism. Results of the prospective investigation of pulmonary embolism diagnosis (PIOPED). The PIOPED Investigators. *JAMA.* 1990;263(20):2753-9.
27. Stein PD, Terrin ML, Hales CA, Palevsky HI, Saltzman HA, Thompson BT, Weg JG. Clinical, laboratory, roentgenographic, and electrocardiographic findings in patients with acute pulmonary embolism and no pre-existing cardiac or pulmonary disease. *Chest.* 1991;100(3):598-603.
28. Stein PD, Afzal A, Henry JW, Villareal CG. Fever in acute pulmonary embolism. *Chest.* 2000;117(1): 39-42.

29. Worsley DF, Alavi A, Aronchick JTT, et al. Chest radiographic findings in patients with acute pulmonary embolism: Observations from the PIOPED study. *Radiology* 1993; 189:133-136.
 30. Ribeiro A, Lindmarker P, Juhlin-Dannfelt A, Johnsson H, Jorfeldt L. Echocardiography Doppler in pulmonary embolism: right ventricular dysfunction as a predictor of mortality rate. *Am Heart J*. 1997;134(3):479-87.
 31. Lenegre J, Gerbaux A, Gay J. L'électrocardiogramme dans l'embolie pulmonaire. In: Denolin H, ed. *L'embolie pulmonaire*. Paris: Masson, 1970;8:211-49.
 32. Ferrari E, Imbert A, Chevalier T, Alain Mihoubi, Philippe Morand, and Marcel Baudouy. The ECG in Pulmonary Embolism* Predictive Value of Negative T Waves in Precordial Leads: 104 Case Reports. *Chest*. 1997;111:537-43.
 33. Ferrari E, Imbert A, Darcourt J, et al. No scintigraphic evidence of myocardial abnormality in severe pulmonary embolism with electrocardiographic signs of anterior ischaemia. *Eur Heart J*. 1995; 16(suppl):269.
 34. Cutforth RH, Oram S. The electrocardiogram in pulmonary embolism. *Br Heart J*. 1958;20:41-54.
 35. Stein PD, Dalen JE, McIntyre KM, et al. The electrocardiogram in acute pulmonary embolism. *Prog Cardiovasc Dis*. 1975;17:247-57.
-